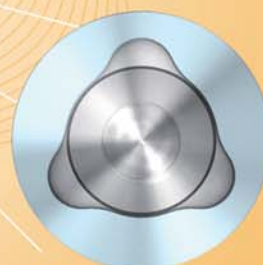
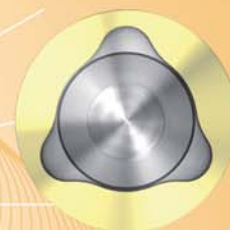


implants

international magazine of oral implantology

1 2010



| case report

Dental Implants—Treatment options for compromised clinical situations

| case report

Safe and effective alternatives to sinus elevation in the atrophic posterior maxilla

| meetings

7th Conference of the Australasian Osseointegration Society



Buccal dehiscence and sinus lift cases

Predictable bone augmentation with synthetic bone material

Authors_ Dr Sérgio Alexandre Gehrke, Brazil & Dr. Giuseppe Maria Famà¹, Italy

_Introduction

The substitution of lost teeth by dental implants is being increasingly used to support prosthetic crowns or bridges. Many of these cases are associated with bone loss that requires the filling of the defects by some kind of bone substitute. The recent improvements in synthetic bone materials have led to increased predictability and explain the ever-increasing use of such materials in various bone augmentation indications.

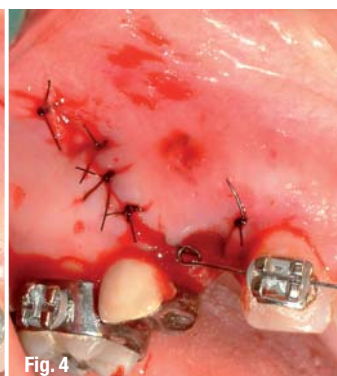
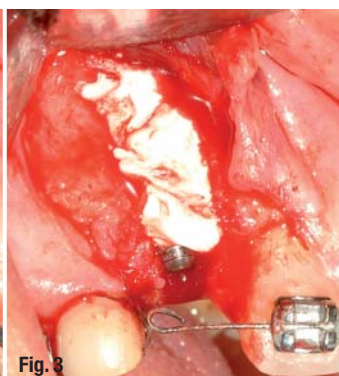
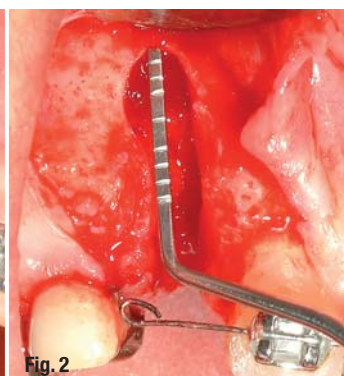
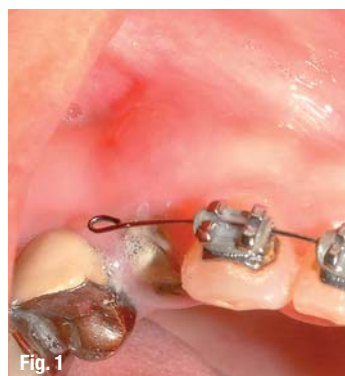Over the last years, one could observe a trend to bring products on the market that seem to be the next generation to supplement granular materials. These are the materials that have their own cohesion and are presented in the form of a paste. Some examples are easy-graft™ (Degradable Solutions, Schlieren, Switzerland), consisting of granules embedded in a sticky polymer matrix, Bond Bone™ (Augma Biomaterials, Karkur, Israel), a hardening calcium sulfate paste, Fortoss Vital (Biocomposites, Staffordshire, England), granules embedded in a hydroxyl sulfate matrix, and PD VitalOs Cement® (Produits Dentaires, Vevey, Switzerland), a hardening

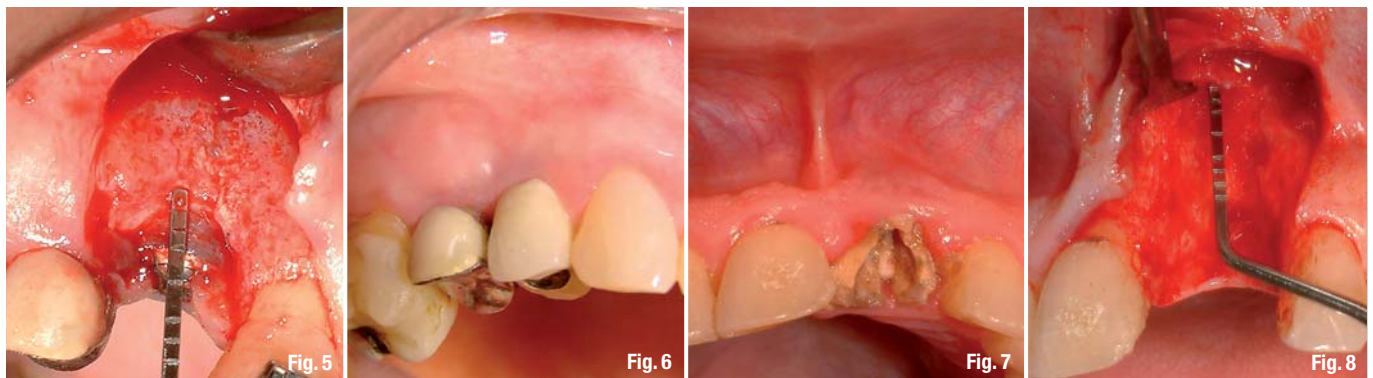
calcium phosphate (brushite) cement. We have been working with the latter material for a couple of years now. The large number of positive results obtained and the ease of use of the cement explain our great satisfaction with the product. Nevertheless, to get good results with this product requires to re-think the way of working because this material, like the pasty materials in general, cannot be placed the same way as one would place granules in a defect.

The goal of this article is to exemplify the positive results obtained with the VitalOs cement in two kinds of indications which seem to be the most adequate indications for the use of this product: immediate implantation and sinus lift in one-step. This is achieved by showing four cases, with an emphasis on how to use the product correctly.

_Immediate implantation in alveolus—Cases presentation

Case 1 was a 50-year old non-smoking female patient in good health who presented with a fractured root at the level of the maxillary first right premolar. This fracture was visible on the radi-





ograph as well as clinically (Fig. 1). The facts that the fracture was old and that a fistula developed around the root resulted in a large loss of the buccal bone wall. The treatment options were presented to the patient, who signed an informed consent form. The patient presented no contra-indications to the treatment.

Case 2 was a 54-year old non-smoking male patient in good health with no contra-indication to the proposed treatment, who presented with a maxillary right central incisor following a root fracture as can be seen on the pre-operative radiograph and clinically (Fig. 7). Given the radiographic and clinical findings it seemed evident that the buccal bone wall was resorbed. The treatment options were presented to the patient, who signed an informed consent form.

Immediate implantation in alveolus—Surgical protocol

After administration of the local anesthetics (Scandicaine 2%, Septodont), an intrasulcular incision was made around the root and a lateral one on the buccal side to provide access and allow visualization of the defect. The fractured roots were very carefully extracted to avoid increase of the bone loss. After curettage, the sites were prepared for the installation of the implant according to the manufacturer's instructions. The bone defects were measured with a periodontal probe with millimeter

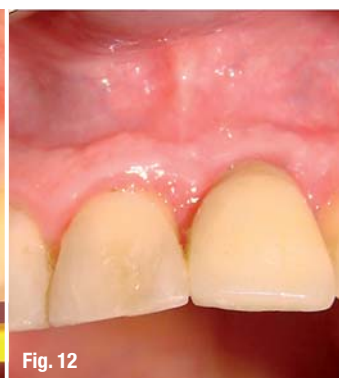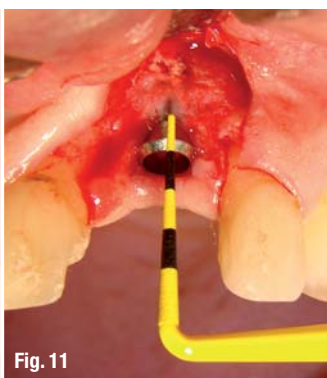
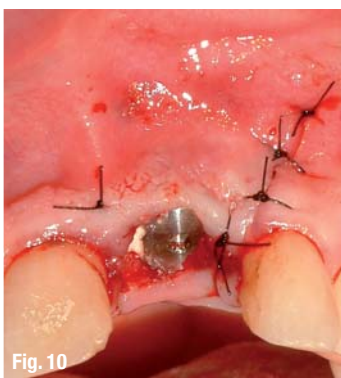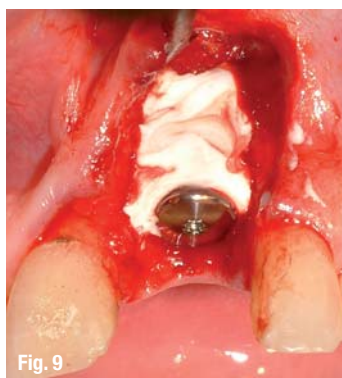markings (Figs. 2 & 8). The implants placed were in each case a Straumann RN SP (4.1 mm diameter, 14 mm length). The implants were installed at the level of the crestal bone of the adjacent teeth.

The injection of VitalOs must always be preceded by adequate control of the bleeding with the suction canula. The cement is placed within the defect without need for over-filling (Figs. 3 & 9), unlike what is often done with other types of bone substitutes like granules. Any material put in excess is always expelled or resorbed. With VitalOs, as the cement forms a block, a large quantity or even the whole material may be expelled. When the injected quantity is in large excess, the hardened block can easily break up and large pieces may be expelled out of the site. With granular materials it is only small granules that are expelled and this is less disturbing than pieces of cement. This is the reason why we never overfill sites with VitalOs.

A suture is then made with a 5-0 nylon suturing material. No attempt is made to achieve primary suture over the implant (Figs. 4 & 10) because we observed that even when the cement remains exposed to the oral environment, the bacteriae cannot adhere onto the surface of VitalOs and therefore no infection develops. The implants with a large platform help to maintain the volume and anatomy of the gums because they act as a shape keeper for the gingiva. A post-operative radiograph is taken for each case 7 days after implantation.

Case	Initial longitudinal measurement of the defect	Initial mesio-distal distance of bone loss (at the ridge level)	Initial area of bone lack in mm ²	Longitudinal defect measurement after 3 months	% of area substituted by bone
1	12 mm	2 mm	82	2 mm	95
2	10 mm	8 mm	132	2 mm	97

Tab. 1 Bone defect measurements (buccal dehiscence cases).



The bone loss area was also measured (with imaging software Image ProPlus 4.0). These results are presented in Table 1.

Immediate implantation in alveolus—Re-opening

The sites were re-opened three months after implant installation to install the healing abutments. Measurement of the buccal bone level was measured again with the periodontal probe (Figs. 5 & 11).

Immediate implantation in alveolus—Restorations

After gingival conditioning, impressions were taken and the prosthetic restorations were made according to manufacturer's (Straumann) instructions. The two cases were followed up after one year and the esthetic result can be seen on Figures 6 and 12. The results show that there was neither loss of tissue nor gingival retraction in the grafted areas. Therefore, the anatomy obtained after implantation was maintained one year after restoration, ensuring a stable esthetic result.

Sinus lift with simultaneous implantation—Cases presentation

Case 1 was a 47-year old non-smoking male patient in good general health with a missing maxil-

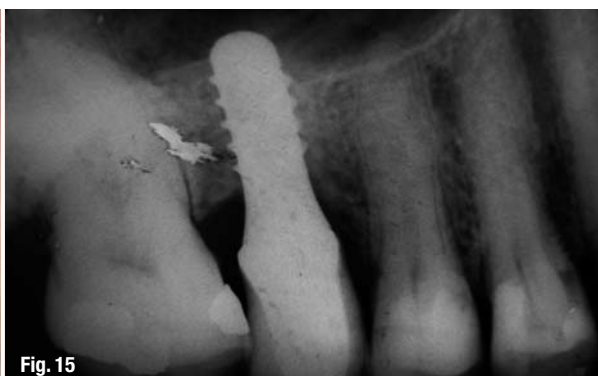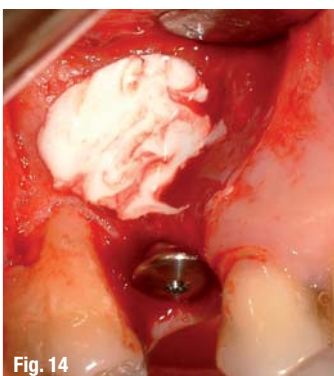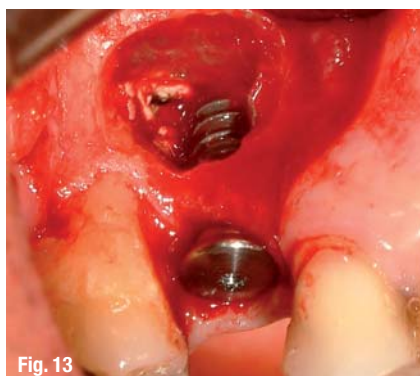lary right second premolar and sinus pneumatization.

Case 2 was a 48-year old non-smoking male patient in good general health with a missing maxillary left first premolar and sinus pneumatization.

In both cases, the sinus pneumatization was an indication for sinus grafting. Since the remaining bone height was larger than 3 mm it was decided to perform a sinus lifting with simultaneous implant installation. The treatment options were presented to the patients and they signed an informed consent form.

Sinus lift with simultaneous implantation—Surgical protocol

After local administration of anesthetics (Scandicaine 2%, Septodont) an intrasulcular incision was performed around the root and a lateral incision was made on the buccal side to gain access to the lateral wall of the maxillary sinus. After creation of the lateral window, the sinus membrane was carefully lifted and the site was prepared for implant installation. Then, the cement was injected against the inner (nasal) sinus cavity up to half of its width, and the implant Straumann RN SP (4.1 mm diameter, 12 mm length) was then installed (Fig. 13). Once the implant installed, the rest of the sinus cavity was filled with the cement (Figs. 14 & 16). The suture was made with 5-0 nylon simple



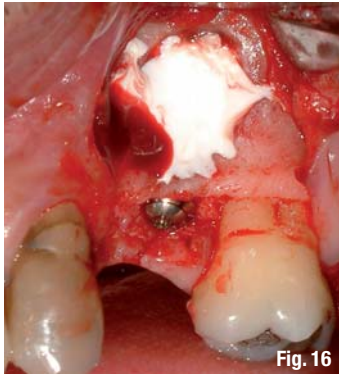

Fig. 16

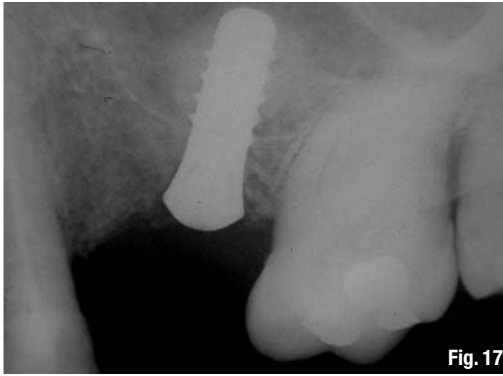


Fig. 17

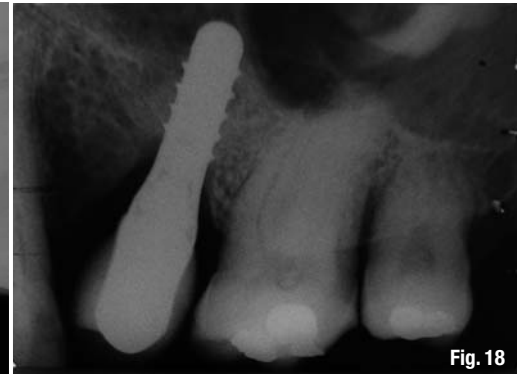


Fig. 18

stitches. A post-operative radiograph was taken 7 days after surgery (Fig. 17). The distance between the sinus floor and the implant apex was measured on the radiograph. The results are shown in Table 2. The patients were recalled after one year to take a radiograph of the treated sites (Figs. 15 & 18).

_Sinus lift with simultaneous implantation—Bone gain measurement

Six months after surgery, the sites were reopened to install the healing abutments. Radiographs were taken to measure the bone gain.

that this material is suitable and very efficient as a bone substitute. This is exemplified here through the presentation of a few cases, representative of the results generally obtained with this material.

The way of delivering the product into the site greatly simplifies its placement: a dual syringe with a mixing tip. Since the product is initially in a pasty form it fills out the site to treat very uniformly and prevents the ingrowth of soft tissues once it has hardened. The sites presented here are situations which offer stability to the cement due to the geometry of the defects. For these reasons,

Case	Initial ridge height	Post-operative distance between original sinus floor and implant apex	Bone height between ridge and new sinus floor after one year
1	3 mm	9 mm	10 mm
2	4 mm	8 mm	9,5 mm

Tab. 2 Bone height measurement (sinus lift cases).

Table 2 shows the values measured post-operatively and one year later.

We already observed that the process of resorption of the cement coupled with new bone growth can be conveniently followed up radiographically (Gehrke 2009). One year after functional restoration we could see that the level of newly formed bone was maintained, without loss around the apical portion of the implants. This is a very positive finding because the loss of bone at the apical level after loading the implants is a common phenomenon when this type of sinus grafting is performed.

_Discussion

Several types of biomaterials and different techniques have been proposed for the recovery of bone tissue lost after tooth extraction or loss. The results obtained with the PD VitalOs cement show

the product is used without membrane. However, a particular attention must be paid to achieving primary stability: if the product is not tightly anchored onto the bone walls or onto an implant surface, then the blood pressure is able to expel part or all of the injected volume. To avoid this situation, it is very important to control bleeding and to choose site geometries that offer stability to the cement.

In our practice we observed the replacement of the cement by bone is generally fast, even though it depends much on the injected volume. This is a very interesting feature because patients choosing the immediate implantation treatment are willing to have the missing element replaced as quickly as possible. The same way, in the case of the maxillary sinus grafting, the cement promotes accelerated bone formation, enabling earlier placement of the restoration.

contact
implants

Dr Sérgio Alexandre Gehrke
 BioFace Institut
 Dr. Bozano, 571
 Santa Maria – RS, Brazil
 E-mail:
 Sergio.gehrke@terra.com.br

¹MD, DDS, Tutor of Periodontology and Implantology at University of Perugia